

# UG MANUAL

## TABLE OF CONTENTS

<b>Title</b>	<b>Page</b>
Operative dentistry basics	02
Bases and Liners	03
Matrices and Wedges	07
Amalgam Restorations	10
Composite Restorations:	14
Class 5 Lesion-Glass Ionomer	21
Restoration Repair	24

# Operative Dentistry Basics

---

Clinic hours are 9:30 am to 12:30 pm. Students must be done with the treatment and the patient dismissed by 12:15 to allow time to write the treatment note and receive feedback from faculty.

**Students should only do procedures that have been approved by the patient using a treatment plan.**

1. At start check verify:
  - a. Extent and design of preparation you feel is needed with faculty.
  - b. Material selection should also be verified.
  - c. Consider if additional materials such as pins, liners or alternate matrix systems may be needed.
2. Generally, for larger lesions, the initial preparation check would be an ideal amalgam preparation.

**Do not make a preparation larger than what you have been given permission to do!**

3. For smaller lesions that may be restored using a more conservative resin preparation, the initial outline may be just a fissurotomy done to remove stain from the affected grooves.
4. Once the initial preparation is done the student must verify the modifications they feel are needed to remove any adjacent unsupported enamel or caries. Use of correct dental terminology such as “Deepen” (For axial and pulpal walls) or “Extend” (Other walls) is important. Removal of tooth structure without faculty permission may result in loss of clinical privileges.
5. The student should make all efforts to avoid a pulp exposure.
6. Rubber dam isolation should be used unless permission given to use alternate method.
7. Before removing the RD have faculty check restoration for open margins or voids.
8. Final restoration check should reflect ideal occlusion, anatomy and polish.

A restoration that fails to meet minimal standards will not be taken to complete and the student may need to repeat the procedure or repair the restoration in some manner.

9. Daily grades WILL be significantly reduced for procedures where the student fails to prepare adequately, starts late, fails to follow directions; or performs procedures without permission.
10. Notes must be written within 24 hours of the procedure. It is the student’s responsibility to ensure faculty have approved the procedure and note.

## Matrix Bands and Wedges

---

### Before you come to clinic:

1. **Review** Operative dentistry book: 1) Condensation and Carving Class II 2) Class III restorations 3) Class IV 4) Posterior Tooth Cusp Replacement Using Resin Composite and Esthetics
2. Read **textbook** Summit's Fundamentals of Operative Dentistry 4th Ed. Pages 260-264, 299-300, 347-350, 297-298.
3. **Understand** that for different locations (anterior vs. posterior) and different types of materials (amalgam, composite, Comp Core, II LC) different wedges and matrices are required.

### Types of Matrix systems:

- I. **Sectional Matrix Systems**
- II. **Automatrix System** – can use for Class II, Cusp Replacements, Core Buildups,
- III. **Cervical Matrices**- Class V resin restorations – 3 sizes
- IV. **Clear Matrix** (Mylar strips) for Class III, IV
- V. **Tofflemire** with metal matrix bands – can be used for Class II, Cusp replacements, Core buildups. May be used also with lingual approach.





## Amalgam Restorations

---

### Before you come to clinic:

1. Read notes from Operative Lecture titled “Amalgam Restoration Class II”
2. Review section on “Matrices and Wedges” . Think ahead on which system will work best for this restoration.

### Get the following items:

Item	Picture or Procedure	Associated supplies	From
Rubber dam cassette Class 2, 3-Tofflemire retainer			Window
Rubber dam (See section on “Rubber Dam” for supplies) Matrix		Wooden wedges 	Operative supplies
Copalite varnish Optional		Microbrushes. Do not use directly from bottle. Place a few drops in medicine cup	Operative supplies
Amalgam capsules			Operative supplies

**TOOTH PREPARATION** : is the mechanical alteration of a defective ,injured ,or diseased tooth to receive a restorative material that re-establishes a healthy state for the tooth,including esthetic corrections where indicated and normal form and function. STURDEVANT

### CLASSIFICATION OF TOOTH PREPARATION

**CLASS I:** 1. pit and fissures on the occlusal surfaces of molars and premolars.  
 2. facial or lingual pits of molars.  
 3. lingual pits of maxillary incisors.

**CLASS II:** proximal surfaces of posterior teeth.

**CLASS III:** interproximal surfaces of anterior teeth without incisal edge involvement.

**CLASS IV:** interproximal surfaces of anterior teeth with incisal edge involvement.

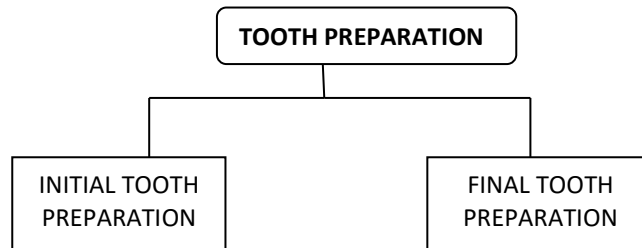
**CLASS V:** gingival 1/3<sup>rd</sup> or cervical third of facial or lingual surfaces of the tooth.

**CLASS VI:** 1. incisal edge of anterior teeth.  
 2. cusp tips of posterior teeth.

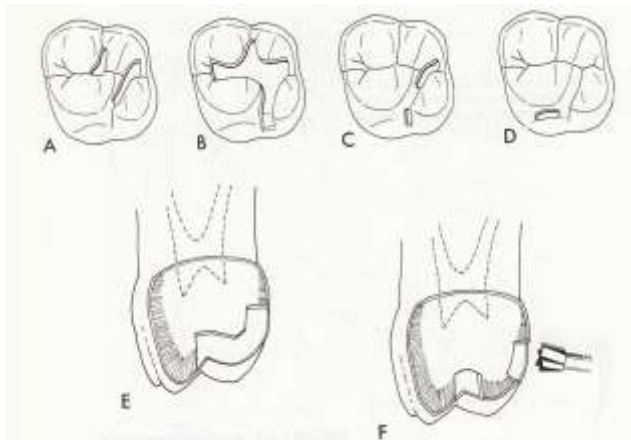
### CLASS I CAVITY PREPARATION

CONSERVATIVE CLASS I AMALGAM RESTORATION:

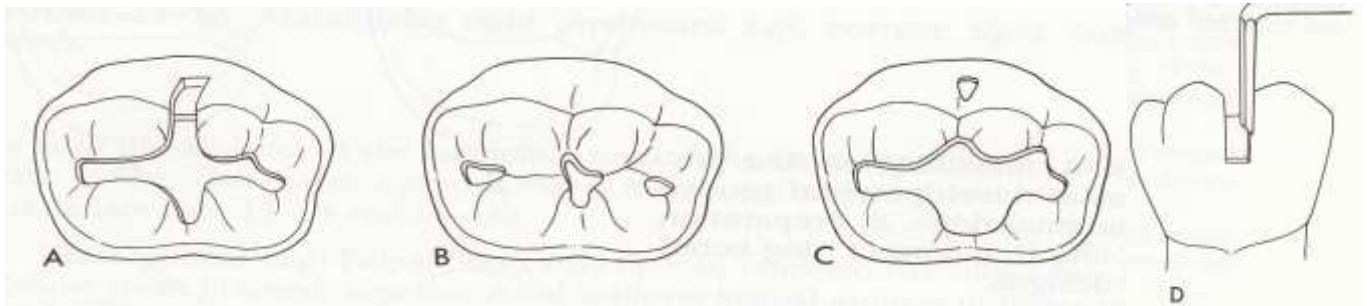
- It is recommended to **protect the pulp**.
- **preserve strength** of the tooth.
- To **reduce deterioration** of the amalgam restoration.



### VARIATION IN DESIGN OF MAXILLARY FIRST MOLAR



## VARIATION IN DESIGN OF MANDIBULAR FIRST MOLAR



### ARMAMENTARIUM:

1. Bur

Nos. ½, 330, 245

Nos. 35, 37, slow speed

2. Hand instruments

Excavators

Enamel hatches

Bin-angle chisels

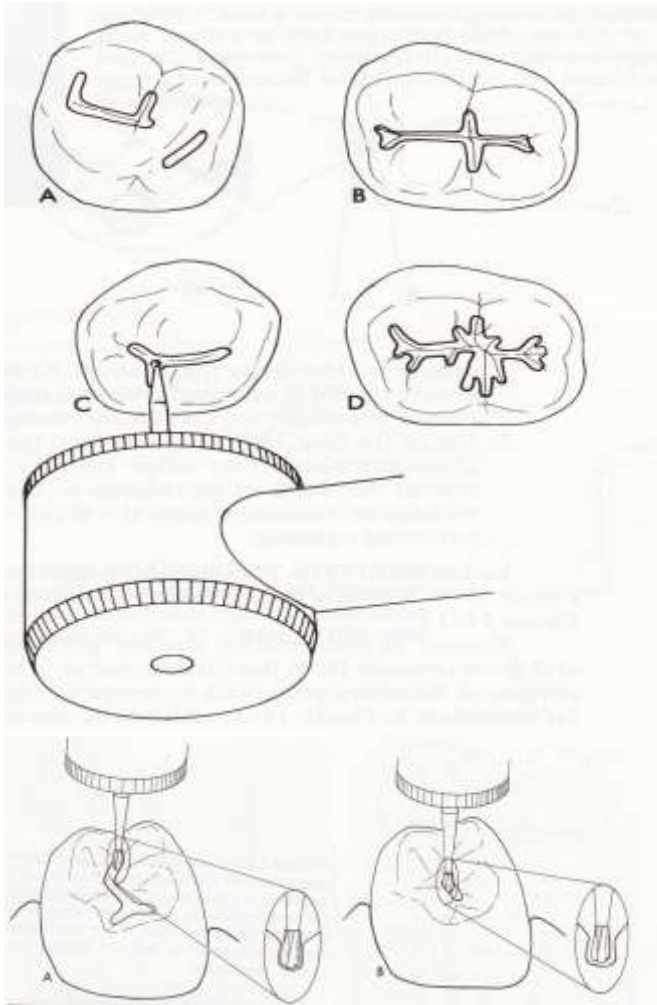
Curved Wedelstaedt chisel

### SEQUENCE OF PREPARATION:

- **Initial Tooth Preparation:** “establishing the outline form by extension of the external walls to sound tooth structure, while maintaining a specified, limited depth providing resistance and retention forms.
- **Resistance Form:**
  - Features that help the restoration and tooth resist fracturing as a result of occlusal forces.
- **Retention Form:**
  - Features that help lock or retain the restorative material in the tooth.
- **Convenience Form:**
  - Features that make the procedure easier or the area more accessible.

### PROCEDURE:

1. Enter pit with a No. ½ round bur, 2mm deep (1 ½ mm premolars and 3 mm-big molars)
2. Cavity is extended into all grooves, until evidence of defective fissures disappears.



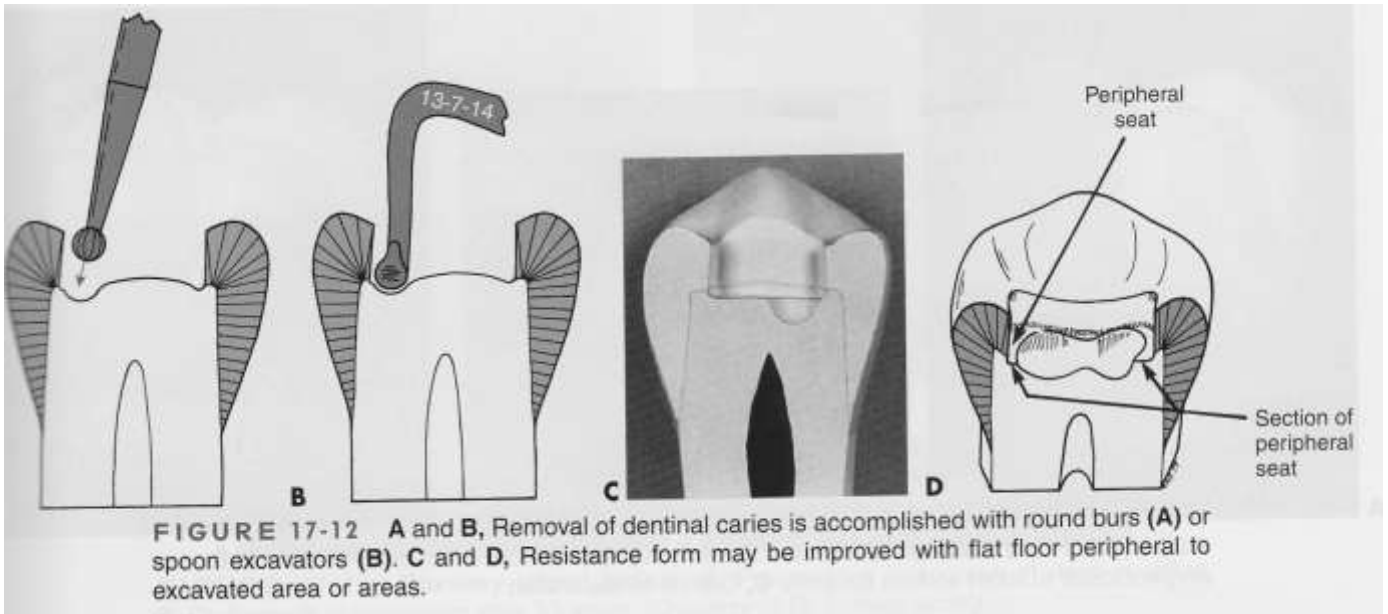
3.. Use of 330 bur is standard for this preparation

- Pilot groove prepared using ½ round burs, “whip”

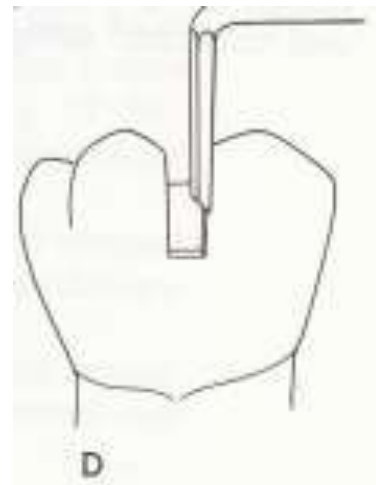
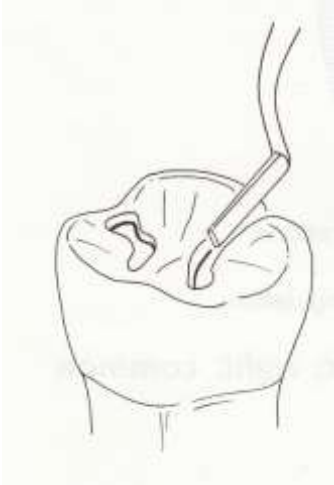4. Pulpal floor flattened with No.35 or 37 slow speed inverted cone bur, likewise for axial walls on lingual grooves for upper molars and facial grooves on lower molars

- In case of deep carious areas, the entire pulpal floor shouldn't be flattened to the same level
- Deep carious areas should be excavated, prepared, treated (liner, base) to level it to the sound pulpal floor
- The resistance form is provided by:
  - Flat pulpal floor, resist forces directed in the long axis of the tooth, strong & stable seat for the restoration
  - Minimal extension of external walls
  - Strong ideal enamel margins
  - Sufficient dept (1.5 mm), adequate thickness of the restoration (fracture & wear)
- The retention form is provided by:
  - Parallelism or slight convergence of two or more opposing, external walls

5. Carious dentin removed with excavator or round bur. Use largest instruments that fits the carious area, safest. Remove from the peripheral DEJ



6. Cement base placed on the deepest portion of the cavity & finished with No. 35 or 37, smooth and flush with adjacent dentin.
7. Enamel margins finished with hand instruments and with high speed burs (330-245) under light pressure.





## CLASS II CAVITY PREPARATION

- ▣ Cavity class II.: involves one or both of the proximal surfaces of the tooth (premolars, molars)
- ▣ Usually the decay starts under the contact area: M, D, M and D surfaces
- ▣ MO,MOD,OD cavity preparation



### Black principles of cavity preparation












- ▣ Opening of the decay
- ▣ Establish the outline form and initial depth (extension for prevention)
- ▣ Primary retention (convergent walls) and resistance form
- ▣ Obtain the convenience form
- ▣ Remove any remaining carious dentin or old restorative materials
- ▣ Pulp protection
- ▣ Secondary retention (undercuts) and resistance form
- ▣ Finishing the walls (remove the unsupported enamel)
- ▣ Clean and check the cavity

### Instruments of the cavity preparation

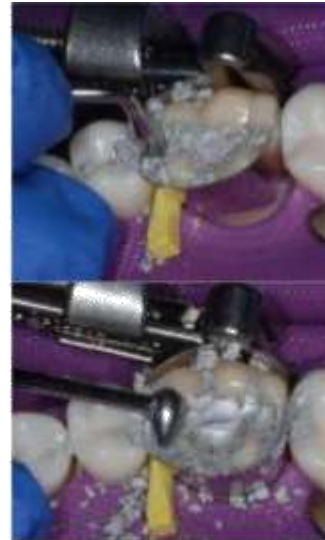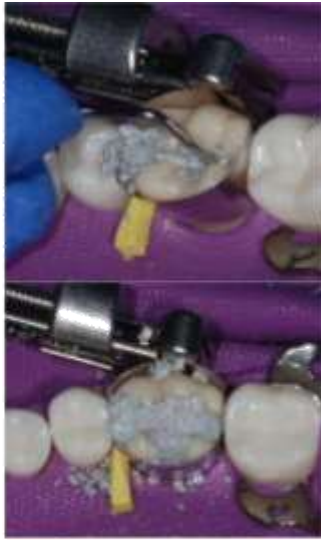- ▣ Pear shaped bur (inverted cone bur- 5-8 degree occlusal convergence) is advocated for tooth preparations for amalgam restoration, high speed accompanied with water spray
- ▣ Low speed, round bur advocated for the removal of the deepest part of carious dentin and previous tooth filling remnants.

### Procedure:

Steps	Pictures*	Tips, Thoughts, and Details
<b>1. Determine whether liner is indicated.</b> Apply liners or Copalite varnish		Liner indicated if this is the first restoration the tooth has received or if patient has a history of sensitivity to new restorations. If lesion is deep, see section on Vital Pulp Therapy.
<b>2. Pre burnish matrix</b>		
<b>3. Fit the matrix</b> onto the tooth  <b>4. Wedge-</b> Place wedge with cotton pliers or hemostat		

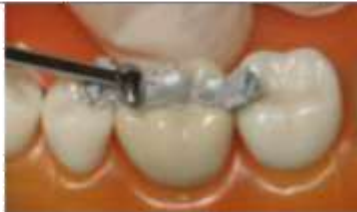		<p>1. Band should contact adjacent tooth (burnish)*  2. Contact should be convex, and at junc.  O/M 1/3</p> 
<p>5. Triturate amalgam</p>		<p>Setting: Turtle  Time: Blue(2 spill) or green (1 spill)  14 sec ± 3 sec  <u>Adjust time based on consistency:</u>  Too crumbly- increase time 2 sec  Hot, shiny, sticks to capsule- decrease time 2 sec</p>
<p>6. Transfer amalgam</p>	 	<p><b>Start</b> with the small end of one carrier <b>ONLY</b>.  When you have condensed over the floor and all retentive elements, switch to larger carrier.</p>
<p>7. Condense general</p> <p>a. Small condenser first</p>	 	<p>Thoroughly condense <b>each increment</b> before adding more amalgam. Small condenser for pulpal line angles.</p>
<p>b. Large condenser</p>	 	<p>Ensures that marginal amalgam is well condensed before carving</p> <p>Condense about 1 mm of amalgam above the cavosurface margin</p>
<p>c. Class II</p> <p>a. <u>Box area first</u>, using small increment of amalgam and small condenser.</p> <p>Condense into the line angles and against the matrix band</p>		

b. Following increments.  
After floor and retentive features are condensed, switch to using the large carrier and larger condenser.



c. Overfill the cavity with a generous amount of amalgam

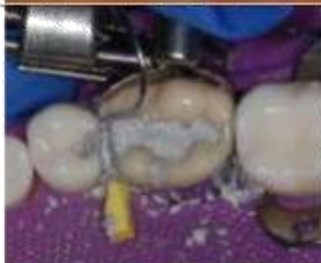
### 8. Pre-burnish



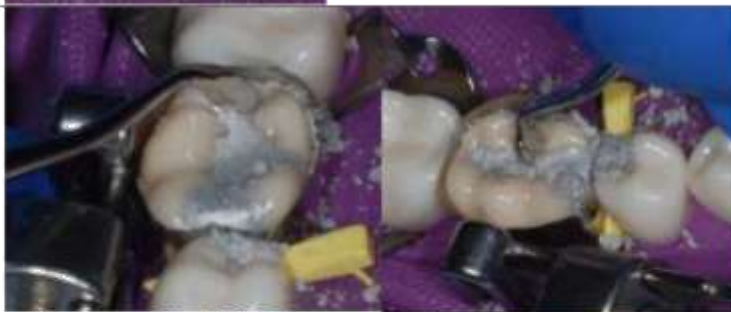Use football and beaver tail burnisher. Smooth amalgam against margins to leave a thin layer.

### 9. Carve

a. Define contact area, marginal ridge and occlusal embrasure

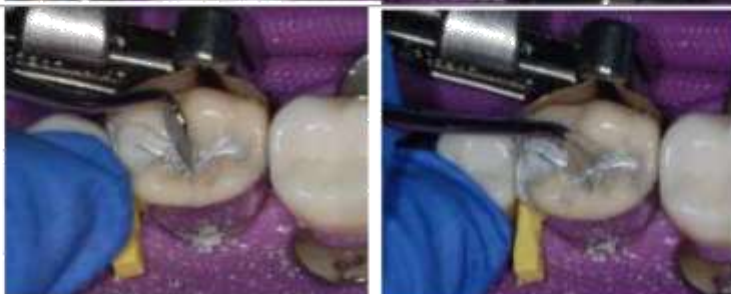





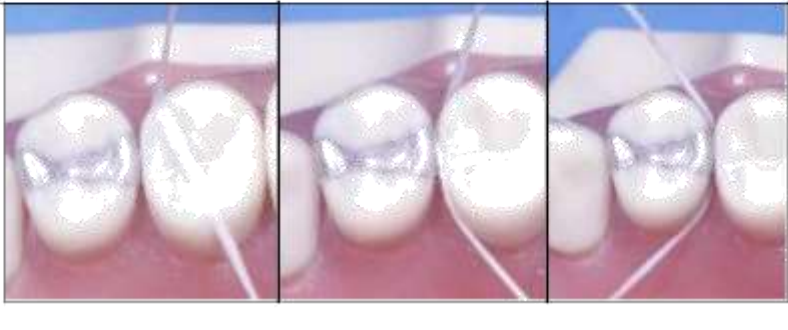
b. Find outline of the preparation with large cleoid



c. Rough out occlusal anatomy

Define occlusal pits then join with groove using cleoid end or Instrument: #21



<p><b>10. Remove the matrix retainer first, then the wedge, then matrix</b></p>		
<p><b>11. Remove interproximal flash using interproximal carving instrument</b></p>		
<p><b>12. Create correct embrasure form</b></p>		
<p><b>13. Occlusion</b></p>		<p>Do not allow the patient to bite down initially. Gently guide them into a centric occlusion, then insert a piece of articulating paper and have them gently tap. Adjust high spot. When centric occlusion is finalized, have pt into working and non-working movement make sure the occlusion is clear as well.</p>
<p><b>14. Finishing:</b> Check Contact/ Gingival margins (overhang)</p>		

**Pitfalls:**








1. Open contact- from not pre-burnishing the matrix band or wedging the tooth firmly enough
2. Overhang- Not ensuring that the matrix band is sealed prior to condensation or condensing down in to the box at an outward angle rather than aiming into the tooth.



## Composite Restorations

### Before you come to clinic:



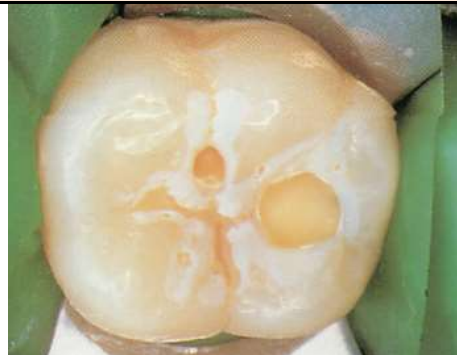
Read **notes** on Composites



### Get the following items:






Item	Picture or Procedure	From
<b>All composites</b>		
Rubber dam cassette Rubber dam		Window Operative supplies
Vita Shade guide		Window
37% phosphoric acid (Bisco) Primer & adhesive system (Optibond FL)		Window Operative supplies
Composite resin (Point 4 or Premise)		Operative supplies
<b>Class II, Add:</b>		
Tofflemire matrix system <b>OR</b> Sectional matrix system		Operative supplies
		Window
Wooden wedges		Operative supplies
Finishing kit Enhance points/cups		Window Operative supplies

Class III and IV, Add:		
Mylar Strip/wedges		
Finishing kit Soflex-discs Enhance points/cups		Window Operative supplies







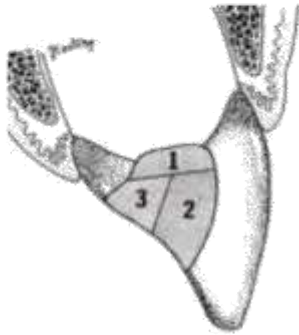
### Procedure:









Steps	Pictures*	Tips & Thoughts
<b>All composites</b>		
1. <b>Determine shade</b> before placing rubber dam		The tooth will turn several shades lighter within minutes after isolation
2. Rubber dam placement	See section on Rubber Dam Placement 	<b>Mandatory-</b> composite is sensitive to moisture-working without a rubber dam seriously degrades the quality of the restoration.
<b>3. Preparation:</b>		
<b>Class I, V</b>		
Just remove the decay and unsupported enamel- no need for a flat floor or sharp angles of any sort Do not <b>bevel</b> occlusal surfaces		Consider sealing grooves that may not be coalesced but are not carious

Class II		
<p><b>Design-</b> Remove decay, then develop the outline based only on the need for convenience and clearance form-.</p> <p><b>Bevel</b> facial and lingual margins, but not occlusal.</p> <p><b>If gingival box extends below enamel,</b> consider doing an “open sandwich” resin modified glass ionomer layer up to the area of sound enamel.</p>		<p>No need to cut a dovetail in the occlusal.</p> <p>Consider sealing grooves that may not be coalesced but are not carious</p>
Class III		
<p><b>Design-</b>Remove decay and unsupported enamel.</p> <p><b>Bevel</b> facial and lingual margins.</p> <p><b>If gingival box extends below enamel,</b> consider doing an “open sandwich” resin modified glass ionomer layer up to the area of sound enamel.</p>		<p>This illustration shows Dycal in place, but only use it if you are near (blushing deep!) the pulp. Not used routinely.</p>
Class IV		
<p><b>Design-</b> Remove decay and unsupported enamel</p> <p><b>Bevel</b> all cavosurface margins</p> <p><b>If gingival box extends below enamel,</b> consider doing an “open sandwich” resin modified glass ionomer layer up to the area of sound enamel.</p>		 <p>Black lines indicate bevel.</p>

<b>4. Place pulp protection (if necessary). See section on “Bases and Liners”</b>		
<b>5. Place matrix- See choices in section on “Matrix Selection”</b>		
<b>Class II</b> (options on type of matrix)		Matrix should make contact with the adjacent tooth Band should be below the gingival margin
<b>Class III, Class IV</b>  Place clear plastic matrix below level of margin, then place wedge		Do not touch embrasures with fingers.
<b>6. Bonding to enamel and dentin</b>		
Apply 37% phosphoric acid <b>etching gel</b> to enamel and dentin for 15-20 sec. <b>Rinse</b> with water stream only (not air/water mix) for 15 sec <b>Remove excess water</b> with suction or brief air stream.		Do not desiccate dentin!
Apply <b>Primer</b> with applicator (light scrubbing motion, 5 seconds)  Gently <b>air dry</b> to remove the solvent.(15 seconds)		Use Optiguard FL for priming and bonding. Instructions are on the back of the package.  Dentin surface should appear shiny
<b>Apply bonding agent</b> (Optibond) with applicator.  <b>Light cure</b> for 20 sec		Do not apply too much adhesive. A thick adhesive layer leaves the weaker, unfilled resin at the margin, and it will look like decay on a radiograph.



<p><b>7. Place compule in the composite gun, express the first part of composite in compule and discard.</b></p>		<p>The material in the tip is usually dried out</p> 
<p><b>8. Apply composite in increments, optimally 1-2 mm.</b>  <i>Before you start, move light of the dental unit away from the restoration, and cover your head lamp</i></p>		
<p><b>Class I, V:</b></p> <p><b>a. First Increment-</b> 1 mm across Floor</p> <p><b>b. Following increments-</b> diagonally in 1-2 mm thickness Remember, this prep has the highest C-factor of 5!</p>	<p><b>Class1:</b></p> 	<p><b>Class V</b></p> 
<p><b>Class II:</b></p> <p><b>a. First increment</b></p> <p><b>b. Following increments</b></p> <p><b>c. Last increment</b></p>		<p>Place first increment in box Light cure for 20 seconds</p> <p>Add increments of 2 mm diagonally on one enamel margin at a time. Light cure 20 sec after each increment.</p> <p>Sculpt composite to the desire anatomy</p>
<p><b>Class III, IV</b></p> <p><b>a. First increment</b> along prep floor</p> <p><b>b. Following increments</b> to the facial or lingual.</p>		

<p><b>9. Cure for 20 sec with LED curing light (cordless)</b></p> <p>or 40 sec for Quartz Tungsten Halogen light (corded)</p>		<p>Aim at the restoration</p> <p>Moving tip 1-2m back &amp; forth may reduce adverse effects of curing light 'hot spots'</p>
<p><b>10. Remove matrix band</b></p>		
<p><b>11. Shape and contour</b></p>		
<p><b>a. Contour with football bur or slow speed #4 bur</b></p> <p><b>Occlusals on Class I, II</b> <b>Linguals of Class III, IV</b></p>		<p>Follow the contours of the tooth. A slow speed bur will allow you to feel the enamel better.</p>
<p><b>b. Contour with flame bur</b></p> <p><b>Class V</b> <b>Facials of Class III, IV</b> <b>All embrasures</b></p>		<p>Angle the bur to reproduce the convexity/concavity of the tooth</p>
<p><b>12. Polish</b></p>		
<p><b>a. Polish interproximals with abrasive strips.</b></p> 		<p>Use <b>abrasive strips</b> in this order:</p> <p>Dark end of gray strip Light end of gray strip Blue strip</p> <p>There is a half-width gray strip available for polishing gingival without opening contact.</p>
<p><b>b. Polish occlusal, lingual, and Class V with polishing points</b></p>		<p><b>Be sure you don't heat the tooth with this step!!!</b></p> <p>Light, intermittent touch Keep blowing with air</p>
<p><b>c. Polish large flat surfaces; facials of Class IV, large Class V with disks</b></p>		<p>Use Sof-Lex <b>disks</b> in this order:</p> <p>Coarse-brown Medium-orange Fine-gold Extra fine-yellow</p> 

<p><b>13. Consider using Optiguard</b>  <b>a. Etch</b> with phosphoric acid gel  <b>b. Rinse 15 sec</b>  <b>c. Dry</b> as much as possible  <b>d. Apply</b> with a <i>microbrush</i> barely damp with Optiguard.  <b>e. Light cure 20 sec</b></p>		
<p><b>13. Finishing:</b>  <b>Check Contact/ Gingival margins (overhang), using dental floss. Repair, or polish as needed</b></p>		
<p><b>14. Remove rubber dam</b></p>		
<p><b>15. Check occlusion</b></p>		

### Pitfalls:

- 1. Open Contact.** You must contour the band and ensure a good contact prior to placement of restorative material. Since you aren't condensing (like amalgam), you won't get any more pressure against the contact area.
- 2. Removing enamel while contouring.** Use the football bur only on lingual surface of anteriors or occlusal surface.
- 3. Gingival overhang.** This is very annoying because it is difficult to remove and takes a LOT of time and elbow grease with polishing strips. Wedge very carefully and pull the matrix band to contour against the tooth surface as best you can.

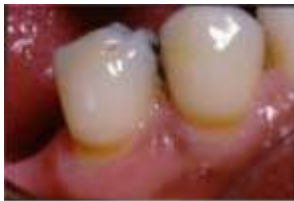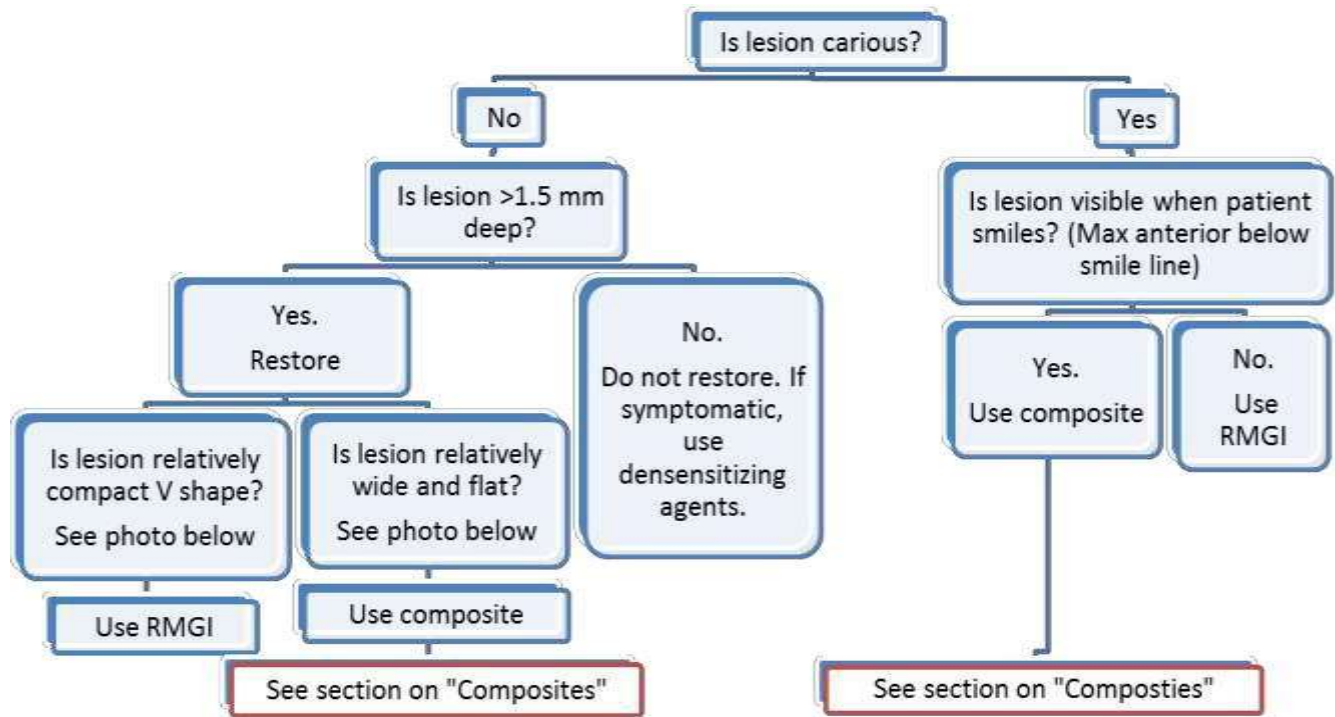
### What to tell the patient after you are done:

**Possible post-operative sensitivity.** They should call you if this happens, and you can consider resealing the surface with Optiguard at the next appointment.

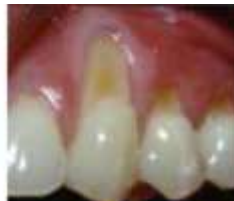## Class V Lesions

### Before you come to clinic:

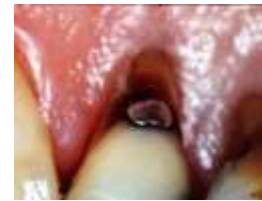1. Read notes from Operative Lecture titled "Restoration of Non-Carious Class V Lesions" and "Class V Composites"
2. Understand indications for these procedures:



Non-carious, V-shaped lesion



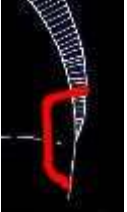








Non-carious, wide/flat lesion



Carious lesion

**Procedure:**

Steps	Pictures*	Tips & Thoughts
<b>Technique for Glass Ionomer</b>		
<p><b>1. Determine Vita Classic shade</b></p>		<p>Usually dark shade , because the cervical third is darker than other thirds.</p>
<p><b>2. Isolation</b></p> <p><b>Composite-</b> Rubber dam is best</p> <p><b>RMGI-</b> Can use cotton rolls, dry angle isolation. May need retraction cord if margin of lesion is at or below level of gingiva</p>		
<b>3. Preparation</b>		
<p>RMGI Prep –Enamel</p>  <p>No need for bevels on cavosurface Margins No need for retention grooves</p>	<p>RMGI Prep –CEJ (large)</p>  <p>Note: some instructors may ask you to roughen surface, to improve retention</p>	<p>RMGI Prep –CEJ (abfraction)</p>  <p>Lesions should be <b>2 mm</b> deep before they should be restored</p>
<p><b>4. Preparing surface</b></p> <p><b>a. Clean lesion</b> and adjacent tooth structure with plain pumice (Preppies), rinse</p> <p><b>b. Scrub lesion</b> and margins with a microbrush and <b>GC Cavity Conditioner (polyacrylic acid)</b> for 10 sec, rinse, lightly dry</p>		<p>Remove bulk of water but keep the surface moist. Best done by putting high speed suction over prep for 5-10 seconds.</p> <p>Be careful to avoid saliva Contamination</p>




<p><b>4. Mixing</b></p> <p><b>a. Tap capsule</b> on a flat surface to fluff the powder</p> <p><b>b. Activate capsule</b> by depressing the button on the bottom</p> <p><b>c. Triturate</b> for 10 sec on Rabbit Setting</p>		<p>There is an activating tool if you want to use it- usually comes packaged with the applicator gun.</p>
<p><b>5. Place material.</b> Inject Fuji II LC into internal form of lesion from distal to mesial, allow excess to cover margins and produce approximately 30% over-contour.</p>		<p>This material does not shrink on curing, so bulk filling is best.</p>
<p><b>6. Remove excess</b> only on mesial and distal ends of lesion with one mesial or distal motion of gold resin instrument, removing any excess from interdental papilla.</p> <p><b>7. Light cure 20 seconds.</b></p>		<p><b>Do not try to sculpt RMGI like resin composite, it is too sticky.</b></p> <p>You will end up with a void on the gingival margin if you do more than suggested.</p>
<p><b>8. Contour restoration</b> with flame shaped finishing bur at stall speed, using water spray, in high speed handpiece.</p>		
<p><b>9. Finish restoration</b> wet, using very light pressure, medium Sof-Lex disk (light orange) or rubber composite polishing point.</p> <p><b>10. Remove retraction cord.</b></p>		<p>Surface will not polish.</p>

## Repair of Restorations

### Before you come to clinic:

Understand that minor marginal caries adjacent to crowns, and sometimes adjacent to large direct restorations, can often be repaired with a glass ionomer restoration. Understand that resin composites are usually the worst choice for repairs because they do not bond/seal well with old restorations.

### Get the following items:

Item	Picture or Procedure	Associated supplies	From
Cotton rolls Dry angles Ultrapack retraction cord			Operative supplies
GC conditioner Fuji II LC capsules		Fuji II LC applicator Gun Microbrushes	Operative supplies
Finishing kit Small Soflex discs (medium, fine)			Window Operative supplies

### Procedure:

1. Promise the patient only that you will try to repair his/her crown.
2. Place retraction cord to displace nearby gingiva. (If the caries extends interproximally this will be evident here. Normally, access will prevent a repair under these circumstances.)
3. Make a retentive amalgam-style preparation. Some of the crown margin will normally be removed to establish a caries-free occlusal/incisal wall.
4. Condition, restore and finish as usual with Fuji II LC.